

## Modern Therapeutic Approaches and Concepts for the Treatment of Trichophytosis in Calves

Vusala Sardarly<sup>1\*</sup> , Ramil Mammadov<sup>2</sup> , Konul Dunyamaliyeva<sup>3</sup> ,  
Sevinj Novruzova<sup>3</sup> , Nargiz Huseynova<sup>3</sup> 

**Abstract.** *The aim of the present study was isolating and identifying the causative agents of ringworm in cattle and to comparatively evaluate the therapeutic efficacy of the LTF-201 “Arm” vaccine in the treatment of calf trichophytosis when used in combination with the immunomodulator Mixoferon and the topical etiotropic agent Akamixsan. The study was carried out at a private farm owned by Veli Kuliev, located in the Karaarkh settlement of the Samukh district, as well as at the regional veterinary diagnostic laboratory. During clinical examination of 150 calves, signs of dermatophytosis were detected in 30 animals (20%). To confirm the diagnosis, skin scrapings were collected from the border between affected and healthy skin areas of suspected animals. The samples were subjected to direct microscopic examination and inoculated onto mycobiotic culture media followed by incubation at 25 °C. Mycological examination resulted in the isolation and identification of fungi belonging to the genus Trichophyton from diseased calves. To assess treatment efficacy, 30 affected calves were divided into two groups of 15 animals each. Calves in the first group received the LTF-201 “Arm” vaccine intramuscularly at a dose of 2 mL, the immunomodulatory Mixoferon at a dose of 2000 IU/kg, and topical application of Akamixsan to the affected skin areas. Animals in the second group received the LTF-201 “Arm” vaccine at a dose of 2 mL and topical treatment with Akamixsan without administration of Mixoferon. It was established that calves affected by trichophytosis developed secondary immunodeficiency predominantly involving the humoral component of the immune system. During the active stage of the disease, interferon levels decreased by more than 2.5-fold, accompanied by a reduction in the bactericidal and lysozyme activity of blood serum compared with clinically healthy animals. The use of the LTF-201 “Arm” vaccine in combination with Mixoferon provided more rapid restoration of nonspecific resistance parameters, accelerated reparative processes in the skin and regrowth of hair, and significantly reduced the time to clinical recovery compared with the treatment regimen without immunomodulatory support.*

**Keywords:** *dermatophytosis, LTF-201 “Arm” vaccine, Mixoferon, Akamixsan, blood sampling, bactericidal and lysozyme activity of serum, immunomodulator*

<sup>1</sup>Azerbaijan State Agrarian University, PhD of Biology, Ganja, Azerbaijan

<sup>2</sup>Azerbaijan State Agrarian University, PhD of Agrarian Sciences, Ganja, Azerbaijan

<sup>3</sup>Azerbaijan State Agrarian University, Ganja, Azerbaijan

\*Corresponding author. E-mail: [vusalasardar@hotmail.com](mailto:vusalasardar@hotmail.com)

Received: 9 February 2026; Accepted: 21 April 2026; Published online: 22 June 2026

© The Author(s) 2026. This is an open access article distributed under the terms of the Creative Commons Attribution-NonCommercial 4.0 International License (CC BY-NC 4.0).

## Buzovlarda trixofitiyanın müalicəsinə dair müasir terapevtik yanaşmalar və konsepsiyalar

Vüsalə Sərdarlı<sup>1\*</sup> , Ramil Məmmədov<sup>2</sup> , Könül Dünyamalhyeva<sup>3</sup> ,  
Sevinc Novruzova<sup>3</sup> , Nərgiz Hüseynova<sup>3</sup> 

**Xülasə.** Bu tədqiqatın məqsədi iri buynuzlu heyvanlarda dəmronun törədicilərinin ayrılması və identifikasiyası, həmçinin buzovlarda trixofitiyanın müalicəsində LTF-201 “Arm” vaksininin Mixoferon immunomodulyatoru və Akamixsan yerli etiotrop preparatı ilə birlikdə tətbiqinin terapevtik effektivliyinin müqayisəli şəkildə qiymətləndirilməsi olmuşdur. Tədqiqat Azərbaycan Respublikasının Samux rayonunun Qaraarx qəsəbəsində yerləşən Vəli Quliyevə məxsus özəl fermer təsərrüfatında və Regional Baytarlıq Diaqnostika laboratoriyasında aparılmışdır. 150 baş buzovun klinik müayinəsi zamanı 30 heyvanda (20,0 %) dermatofitozlara xas kliniki əlamətlər aşkar edilmişdir. Diaqnozun təsdiqi məqsədilə şübhəli heyvanların zədələnmiş və sağlam dəri sahələrinin sərhədindən dəri qaşıntıları götürülmüşdür. Alınmış nümunələr birbaşa mikroskopik müayinədən keçirilmiş və mikobiotik qida mühitlərinə əkilərək 25–28 °C temperaturda inkubasiya olunmuşdur. Aparılmış mikoloji tədqiqatlar nəticəsində xəstə buzovlardan *Trichophyton* cinsinə aid dermatofit göbələkləri ayrılmış və identifikasiya edilmişdir. Müalicənin effektivliyini qiymətləndirmək üçün 30 xəstə buzov hər birində 15 baş olmaqla iki qrupa bölünmüşdür. Birinci qrupun heyvanlarına LTF-201 “Arm” vaksini 2 ml dozada əzələdaxili yeridilmiş, Mixoferon 2000 BV/kq dozada tətbiq edilmiş və zədələnmiş dəri sahələrinə Akamixsan preparatı çəkilmişdir. İkinci qrupun heyvanlarına isə LTF-201 “Arm” vaksini və yalnız Akamixsan preparatı tətbiq olunmuş, Mixoferon istifadə edilməmişdir. Müəyyən edilmişdir ki, trixofitiya ilə xəstə buzovlarda əsasən humoral immun sistemini əhatə edən ikincili immunçatışmazlıq inkişaf edir. Xəstəliyin aktiv mərhələsində interferonun səviyyəsi 2,5 dəfədən çox azalır ki, bu da klinik cəhətdən sağlam heyvanlarla müqayisədə qan zərdabının bakterisid və lizozim aktivliyinin aşağı düşməsi ilə müşayiət olunur. LTF-201 “Arm” vaksininin Mixoferon ilə birlikdə tətbiqi qeyri-spesifik rezistentlik göstəricilərinin daha sürətli bərpasını, dəridə reparativ proseslərin və tük örtüyünün regenerasiyasının sürətlənməsini, eləcə də immunomodulyatorsuz müalicə sxemi ilə müqayisədə klinik sağalma müddətinin statistik cəhətdən əhəmiyyətli dərəcədə qısalmasını təmin etmişdir.

**Açar sözlər:** dermatofitoz, LTF-201 “Arm” vaksini, Miksoferon, Akamixsan, qan nümunəsinin götürülməsi, qan zərdabının bakterisid və lizozim aktivliyi, immunomodulyator

<sup>1</sup>Azərbaycan Dövlət Aqrar Universiteti, biologiya üzrə fəlsəfə doktoru, Gəncə, Azərbaycan

<sup>2</sup>Azərbaycan Dövlət Aqrar Universiteti, Aqrar elmlər üzrə fəlsəfə doktoru, Gəncə, Azərbaycan

<sup>3</sup>Azərbaycan Dövlət Aqrar Universiteti, Gəncə, Azərbaycan

\*Məsul müəllif. E-poçt: vusalasardar@hotmail.com

Daxil oldu: 9 Fevral 2026; Qəbul edildi: 21 Aprel 2026; Onlayn dərc edildi: 22 İyun 2026

© Müəllif(lər) 2026. Bu, Creative Commons Attribution-NonCommercial 4.0 Beynəlxalq Lisenziyası (CC BYNC 4.0) şərtləri altında paylanan açıq girişli məqalədir.

### Introduction

At present, dermatophytes in animals are widely distributed and occupy a leading position in the structure of skin and skin appendage diseases (Achterman, 2012, Martinez-Rossi 2017). This is due to the ability of dermatophytes to persist in the external environment for a long time without losing their pathogenic properties. The absence or untimely implementation of diagnostic, therapeutic, and preventive measures contributes to the further spread of the disease (Al-Ani 2002, Bredahl 2000, Chermette 2008, Khosravi 2003).

In livestock complexes and private farms, dermatophytes often occur in the form of enzootics, which is associated with a high level of pathogen carriage among animals (Khmylyov 2019, Moretti, 2013). These diseases are also characterized by pronounced seasonality: the highest number of outbreaks is recorded in the winter–spring period, which correlates with a decrease in the immunoreactivity of the animal organism (Mukhamadiev, et al. 2023, Sargison et al. 2002, Shchelkunova et al., 2012). In recent years, a steady increase has been observed in the number of dermatophyte strains resistant to antifungal drugs used in veterinary practice. The use of existing specific therapeutic and preventive measures does not ensure complete eradication of dermatophytes in farm animals, which necessitates the search for new treatment approaches. One of the promising directions is the development of economically affordable, safe, and highly effective drugs with pronounced antimetabolic activity against dermatophytes (Mitra et al., 1998, Kozlova, 2022, Karibaeva, 2010). Despite the availability of a wide range of medicinal agents used for dermatophytes, the selection of an optimal therapeutic regimen remains a complex task. Therefore, the improvement of treatment strategies for trichophytosis in calves remains highly relevant both scientifically and practically.

**Objective.** The aim of this study was the isolation and identification of the causative agents of ringworm in cattle, as well as a comparative evaluation of the therapeutic efficacy of the LTF-201 “Arm” vaccine in combination with the immunomodulatory Myxoferron and the topical dextrotropic drug Akamiksán, compared with the use of the LTF-201 “Arm” vaccine combined with the topical agent Akamiksán without immunomodulatory support. Additionally, the study aimed to analyze the dynamics of clinical condition in animals during treatment and to determine the duration of reparative recovery in the post-therapeutic period. This allowed the identification of optimal approaches for therapy correction and the development of recommendations to reduce treatment duration and improve overall therapeutic efficacy.



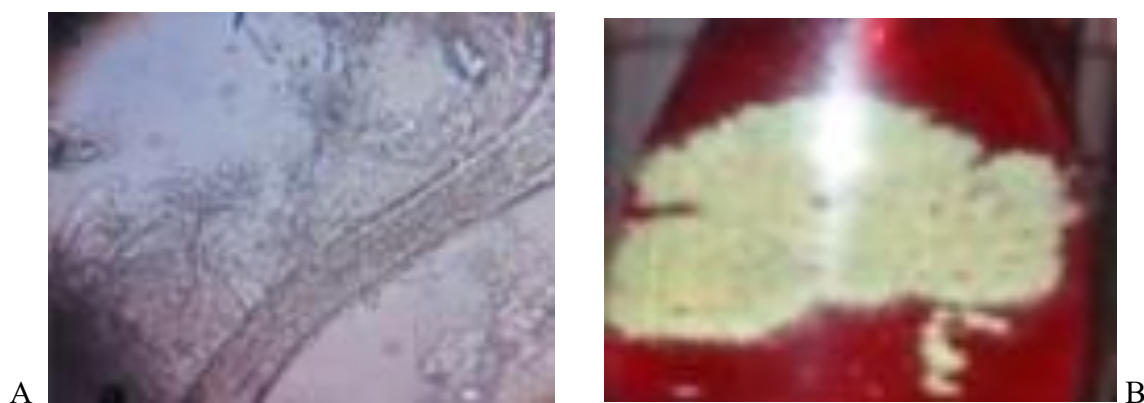
**Figure 1**  
*Diseased animal*

**Sample collection:** Skin scrapings were collected from the periphery of the affected areas after treatment with 70% ethyl alcohol. The collected material was delivered to the regional laboratory for mycological examination.

**Mycological examination:** All samples were examined using direct microscopy for the presence of fungal elements. Skin scales and hair samples were treated with a 10% potassium hydroxide (KOH) solution for 10 minutes, after which microscopic examination was performed to detect fungal hyphae and spores.

Sabouraud medium was used as a nutrient medium for mycological examination for fungal cultivation, as well as a special diagnostic medium, Fung Assay. The Fung Assay medium contains a

pH indicator and additives that inhibit bacteria and saprophytic fungi. When dermatophytes grow on this medium, a change in pH occurs, and the medium turns red.



**Figure 2**  
*A. Fungal hyphae and spores in clinical samples observed during microscopic examination. B. Inoculation of clinical material was performed using Fung Assay medium*

The samples were cultured on nutrient media for several weeks at a temperature of 25°C. From the developed colonies, a fragment of mycelium was collected using a bacteriological loop, transferred into a drop of 50% aqueous glycerol solution, covered with a coverslip, and examined under a microscope. Fluorescent (luminescent) diagnostics were also performed using a Wood's lamp (ultraviolet radiation with a wavelength of 365 nm) in a darkened room. Before examination, the affected skin areas were cleaned of dirt, crusts, and residues of medicinal products. During the examination, the presence of characteristic fluorescence of hair and skin scales was assessed. In the examined calves, no bright emerald-green fluorescence characteristic of infection caused by fungi of the genus *Microspore* was observed. The absence of specific fluorescence suggested that the causative agent of the disease belonged to the genus *Trichophyte*, which was later confirmed by mycological examination results.

For the purpose of performing a biological test and final identification of the causative agent, experimental infection of rabbits was carried out. The study was conducted in accordance with the requirements of the European Convention for the Protection of Vertebrate Animals Used for Experimental and Other Scientific Purposes, adopted on March 18, 1986, with adherence to the principles of humane treatment of laboratory animals. In rabbits experimentally infected with fungi of the genus *Trichophyte*, characteristic skin lesions developed at the inoculation sites three weeks after infection. These lesions were manifested by inflammation, skin scaling, and focal alopecia. Upon repeated mycological examination of material obtained from the affected skin areas, cultures of fungi of the genus *Trichophyte* were again isolated on nutrient media, confirming the etiological role of these pathogens in the development of the disease.

In addition, during the experiment, clinical and immunological parameters of the animals were assessed before and after therapy. The following materials and methods were used:

**Hematological studies:** determination of erythrocyte count, hemoglobin level, and leukocyte count.

**Immunological studies:** assessment of the bactericidal and lysozyme activity of blood serum.

Blood sampling was carried out in the morning before feeding the animals. To obtain serum, a portion of the blood was incubated in a thermostat at a temperature of 37–38°C for 20–30 minutes. After clot formation, the serum was transferred to a refrigerator and stored at 0–15°C until analysis. Using standard methods, the counts of erythrocytes, hemoglobin concentration, leukocytes, and the

leukocyte differential formula in the blood of animals were determined. The number of erythrocytes and leukocytes per 1  $\mu\text{L}$  of blood was measured using an automated “Coulter Counter” (LH module) manufactured by Coultronics France (France), according to the manufacturer’s instructions. A 20  $\mu\text{L}$  sample was diluted (1:10 for erythrocyte counting and 1:10 for leukocyte counting) with filtered 0.9% NaCl solution. During leukocyte counting, erythrocytes were lysed by adding 0.1 mL of a 10% saponin solution.

Hemoglobin in the blood was determined using a special photometer manufactured by Lundberg (Sweden). A 20  $\mu\text{L}$  sample was diluted with 3.5 mL of 0.1 N sodium bicarbonate solution, placed in a cuvette, and measured photometrically. The instrument readings were compared with a special calibration chart. For the determination of the leukocyte formula, blood smears were prepared on degreased glass slides. The air-dried smears were immediately stained using the Pappenheim method, which combines preliminary staining with May–Grünwald stain followed by counterstaining with Romansky–Giemsa stain. The leukocyte differential count was determined according to the Filippchenko method by counting 200 cells using a special laboratory 11-key counter (SL–1). The blood formed elements were expressed in the following units: erythrocytes in millions/ $\mu\text{L}$ , leukocytes in thousands/ $\mu\text{L}$ , hemoglobin in g%, and the relative proportions of individual leukocyte types in percentages.

The bactericidal activity of blood serum (BABS) was determined by the method of O.V. Smirnova and T.A. Kuzmina (1966), modified by I.A. Saladyn (1983). In sterile test tubes, 2.5 mL of meat-peptone broth was added, followed by 0.55 mL of the tested serum; in the control samples, the same volume of broth was added instead of serum. Then, 0.025 mL of a 24-hour broth culture of *Escherichia coli* was added to all tubes. The mixture was thoroughly mixed, after which 1.5 mL samples were taken for nephelometric determination of optical density. The remaining samples were incubated in a thermostat at 39°C for 2 hours and 25 minutes, after which optical density was again measured using an FEC-56M photo-colorimeter with a green filter. BABS was calculated using the standard formula.

The lysozyme activity of blood serum was determined by the method of O.V. Bukharin (1971). In test tubes, 1 mL of the tested serum, 1 mL of 0.5% sodium chloride solution, and 2 mL of a suspension of a 24-hour agar culture of *Micrococcus lysodeikticus* in 0.5% NaCl solution were added. The control sample was prepared in the same way, replacing the serum with physiological saline. Optical density was measured before and after incubation in a thermostat at 37°C for 2.5 hours using a green filter. To study the therapeutic efficacy of the proposed treatment regimens, the affected calves were divided into two groups of 15 animals each.

The animals were treated according to the following scheme:

**Group I:** LTF-201 “Arm” vaccine administered intramuscularly at a dose of 2 mL; Myxoferron administered intramuscularly at a dose of 2000 IU/kg; and topical application of Akamixsan to the affected areas.

**Group II:** LTF-201 “Arm” vaccine administered intramuscularly at a dose of 2 mL; topical application of Akamixsan to the affected areas; Myxoferron was not used.

The LTF-201 “Arm” vaccine is prepared from an attenuated culture of the fungus *Trichophyton verrucosum* TV-201 VGNKI, which is subjected to lyophilization using a protective sucrose–gelatin medium (10% sucrose, 2% gelatin) in a 1:1 ratio. Before use, the vaccine is reconstituted at a ratio of 1  $\text{cm}^3$  of diluent per dose of vaccine. The diluent may be a special diluent for dry vaccines against animal dermatophytes, an isotonic sodium chloride solution, water for injection, or cooled boiled water. For this purpose, the diluent is drawn into a sterile syringe and, under aseptic conditions, injected into the vaccine vial. Upon shaking, the vaccine is rapidly resuspended, forming a

homogeneous suspension. The hair coat at the injection site is first clipped, and the skin is disinfected with 70% ethyl alcohol or another disinfectant solution. During vaccine administration, the rules of asepsis and antisepsis are strictly observed.

**Akamiksan.** Each 1 g contains sulfur – 100 mg, zinc oxide – 100 mg, and the following excipients: salicylic acid – 100 mg, birch tar – 50 mg, sanitary lysol of grade “A” or creolin – 10 mg, purified or gum turpentine – 20 mg, metacid – 5 mg, vaseline – 400 mg, anhydrous lanolin – 170 mg, and purified water – 75 mg (17).

**Myxoferron.** The main active substance of the drug is human recombinant interferon alpha-2b, the production of which is based on recombinant DNA technology.

The general clinical examination of the animals included inspection of the skin and visible mucous membranes, measurement of body temperature, palpation of lymph nodes, and auscultation of the respiratory and cardiovascular systems. The animals were observed over a 14-day period.

**Results of the study.** The study was conducted in two stages. At the first stage, the immunobiological status of the animals was assessed prior to the initiation of therapy.

When determining hematological parameters in diseased calves, a significant increase in the number of blood leukocytes was revealed, while the levels of erythrocytes and hemoglobin remained within the normal range. The data are presented in Table 1. Thus, in diseased calves, the erythrocyte count ranged from  $5.93 \pm 0.62$  to  $6.80 \pm 0.63$  T/L, compared with  $7.7 \pm 0.28$  T/L in healthy animals ( $P < 0.05$ ). Hemoglobin levels ranged from  $110.4 \pm 6.75$  to  $111.5 \pm 6.1$  q/L, compared with  $116.0 \pm 2.3$  q/L in healthy animals ( $P < 0.05$ ). The leukocyte count ranged from  $12.0 \pm 1.70$  to  $10.9 \pm 0.43$  q/L, compared with  $9.5 \pm 0.4$  q/L in healthy animals ( $P < 0.05$ ). Changes in the bactericidal and lysozyme activity of blood serum were also observed. In diseased calves, bactericidal activity ranged from  $31.8 \pm 0.9$  to  $32.2 \pm 1.02\%$ , compared with  $46.5 \pm 1.02\%$  in healthy animals ( $P < 0.05$ ). Lysozyme activity in diseased calves was  $29.1 \pm 2.8$  to  $30.0 \pm 0.8\%$ , compared with  $34.5 \pm 0.70\%$  in healthy animals ( $P < 0.05$ ).

At the second stage of the study, the affected calves were treated according to the following regimen: animals of the first group received an intramuscular injection of the “LTF-201 Arm” vaccine into the neck region at a dose of 2 mL (2 cm<sup>3</sup>). The affected skin areas were treated with Akamiksan ointment without prior removal of crusts or clipping of the hair coat: twice daily during the first 2–3 days, then once daily thereafter. Before application, the Akamiksan container was thoroughly shaken, and for greater efficacy the preparation was gently rubbed into the skin using a swab. In addition, Myxoferron was administered intramuscularly at a dose of 2000 IU/kg.

Calves of the second group received an intramuscular injection of the “LTF-201 Arm” vaccine into the neck region at a dose of 2 cm<sup>3</sup>. The affected skin areas were treated with Akamiksan ointment without prior removal of crusts or clipping of the hair coat: twice daily during the first 2–3 days, then once daily thereafter. Myxoferron was not used. Therapeutic revaccination in both groups was carried out after 14 days. To analyze the dynamics of immunobiological parameters in the animals, blood samples were collected on the 7th day after therapeutic revaccination.

When determining hematological parameters in calves of both treated groups, normalization of erythrocyte and hemoglobin levels was observed, as well as a decrease in leukocyte counts. In calves of the first group, the erythrocyte count was  $7.14 \pm 0.62$  –  $7.2 \pm 0.25$  T/L ( $P < 0.05$ ), hemoglobin level was  $110.4 \pm 0.75$  –  $111.5 \pm 2.1$  q/L ( $P < 0.05$ ), and leukocyte count was  $7.9 \pm 1.70$  –  $8.9 \pm 0.43$  q/L ( $P < 0.05$ ). In calves of the second group, the erythrocyte count was  $6.7 \pm 0.62$  –  $6.80 \pm 0.63$  T/L ( $P$

< 0.05), hemoglobin level was  $91.0 \pm 1.8 - 110.5 \pm 2.6$  q/L ( $P < 0.05$ ), and leukocyte count was  $10.0 \pm 1.70 - 10.9 \pm 0.43$  q/L ( $P < 0.05$ ).

**Table 1**  
*Hematological parameters of calves in both groups after treatment*

Parameter	Group I	Group II	Normal physiological values
Erythrocytes, T/L	$7,14 \pm 0,62 \rightarrow$ $7,2 \pm 0,25$	$6,7 \pm 0,62 \rightarrow$ $6,80 \pm 0,63$	$7,7 \pm 0,28$
Hemoglobin, q/L	$110,4 \pm 0,75 \rightarrow$ $111,5 \pm 2,1$	$91,0 \pm 1,8 \rightarrow$ $110,5 \pm 2,6$	$116,0 \pm 2,3$
Leukocytes, q/L	$7,9 \pm 1,70 \rightarrow$ $8,9 \pm 0,43$	$10,0 \pm 1,70 \rightarrow$ $10,9 \pm 0,43$	$9,5 \pm 0,4$

The obtained data indicate that after the administered treatment, the values of erythrocytes, hemoglobin, and leukocytes in animals of both groups were within physiological norms, reflecting the positive effect of the applied therapy on the functional state of the blood and the overall health of the calves. The bactericidal and lysozyme activity indicators of blood serum in animals of the experimental groups differed significantly. In calves of the first group, serum bactericidal activity was  $45.5 \pm 2.02\%$  ( $P < 0.05$ ), and lysozyme activity was  $34.5 \pm 0.70$  U/mL ( $P < 0.05$ ). In calves of the second group, these parameters were lower: bactericidal activity was  $32.2 \pm 1.02\%$  ( $P < 0.05$ ), and lysozyme activity was  $30.2 \pm 1.02$  U/mL ( $P < 0.05$ ).

**Table 2**  
*Indicators of bactericidal and lysozyme activity of blood serum in calves of the experimental groups*

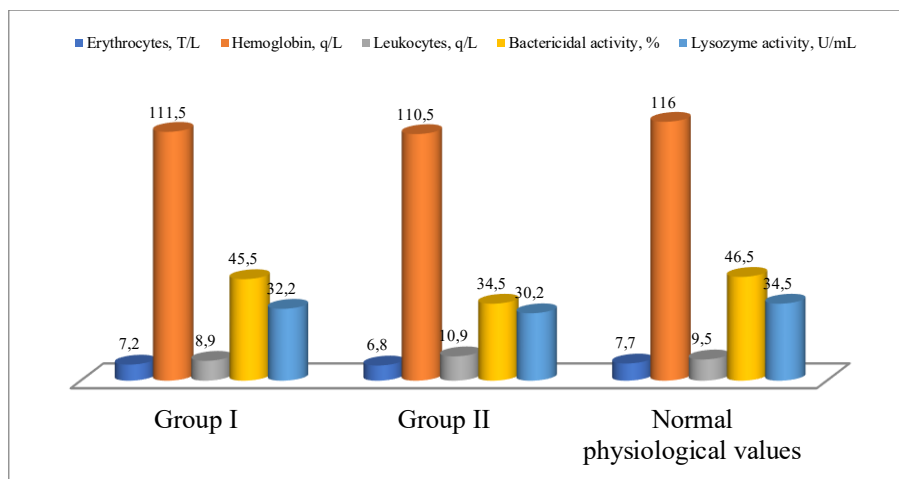
Group	Bactericidal activity, %	Lysozyme activity, U/mL
First group	$45,5 \pm 2,02$	$34,5 \pm 0,70$
Second group	$32,2 \pm 1,02$	$30,2 \pm 1,02$

The conducted study revealed a significant difference in the level of nonspecific immunity between the experimental groups of calves.

The first group demonstrated a high level of bactericidal and lysozyme activity, indicating a more pronounced ability of blood serum to eliminate pathogenic microorganisms and support local immunity.

The second group showed lower values, which indicates a reduced level of nonspecific immune defense of the organism.

Thus, the data confirm that the treatment applied in the first group contributed to a more effective activation of the immune system and an increased resistance of animals to secondary infections. In calves of the first group, the overall therapeutic effect was observed as early as the 10th day after the second vaccine administration. This was manifested by thinning and gradual detachment of trichophytic crusts, as well as the appearance of new hair growth. In calves of the second group, the process of normalization and restoration of the skin and hair coat proceeded more slowly and lasted for about one month.



**Chart 1**  
*Blood parameters of calves in both groups after treatment*

**Table 3**  
*Comparison of the Dynamics of the Therapeutic Effect in the Two Groups*

Parameter	Group I	Group II
Onset of therapeutic effect	10th day after the second administration	Within one month
Clinical manifestations	Thinning and detachment of trichophytic crusts, growth of new hair	Gradual normalization of the skin and hair coat
Duration of recovery	Rapid (within several days after the onset of improvement)	Slow (up to 1 month)
Treatment efficacy	High	Moderate

### Conclusion

The conducted studies demonstrated that after completion of therapy, the hematological parameters in calves of both experimental groups (erythrocyte count, hemoglobin concentration, and leukocyte count) were within physiological limits. This indicates the beneficial effect of the applied treatment regimens on the functional state of the hematopoietic system and the overall condition of the animals. At the same time, significant differences were established in the indicators of nonspecific resistance. In calves of the first group, which received the LTF-201 “Arm” vaccine in combination with the immunomodulator Myxoferron, higher levels of bactericidal and lysozyme activity of blood serum were observed compared with animals of the second group. The combined use of the LTF-201 “Arm” vaccine with Myxoferron provided a statistically significant acceleration of reparative processes in the skin and more intensive restoration of the hair coat. The immunomodulatory effect of Myxoferron promoted a faster recovery of the suppressed components of the immune system to physiological levels, which was accompanied by a reduction in the duration of the main course of treatment.

In calves of the second group, which received the vaccine in combination only with the topical dextrotropic agent, positive dynamics were also observed; however, the processes of skin regeneration and restoration of immunobiological parameters were less pronounced. Thus, the inclusion of the immunomodulatory Myxoferron in the comprehensive treatment regimen for trichophytosis in calves enhances the therapeutic efficacy of the LTF-201 “Arm” vaccine, promotes a faster restoration of immune status, and accelerates the clinical recovery of the animals.

## References

1. Achterman, R. R., & White, T. C. (2012). Dermatophyte virulence factors: Identifying and analyzing genes that may contribute to chronic or acute infections. *International Journal of Microbiology*, 2012, Article 358305, 1–8.  
<https://doi.org/10.1155/2012/358305>
2. Al-Ani, F. K., Younes, F. A., & Al-Rawashdeh, O. F. (2002). Ringworm infection in cattle and horses in Jordan. *Acta Veterinaria Brno*, 71(1), 55–60.  
<https://doi.org/10.2754/avb200271010055>
3. Biohimfarm. (n.d.). *Instructions for use of Akamixsan ointment*. Retrieved June 3, 2026, from <https://biohimfarm.ru/protivoparazitarnie/akamixsan/>
4. Bredahl, L., & Gyllensvaan, C. (2000). Incidence and control of cattle ringworm in Scandinavia. *Mycoses*, 43(Suppl. 1), 8–10.
5. Chermette, R., Ferreiro, L., & Guillot, J. (2008). Dermatophytosis in animals. *Mycopathologia*, 166(5–6), 385–405.  
<https://doi.org/10.1007/s11046-008-9106-7>
6. Karibaeva, A. T. (2010). *Modern clinical, epidemiological and immunological aspects of trichophytosis and microsporia and improvement of therapy* (Doctoral dissertation abstract).
7. Khmylyov, A. G. (2019). *Prevention and therapy of diseases developing against the background of immunodeficiency*. Moscow, Russia.
8. Khosravi, A. R., & Mahmoudi, M. (2003). Dermatophytes isolated from domestic animals in Iran. *Mycoses*, 46(5–6), 222–225.  
<https://doi.org/10.1046/j.1439-0507.2003.00883.x>
9. Kozlova, A. D. (2022). Study of resistance of pathogenic and opportunistic fungi to antifungal drugs. *Veterinary Medicine Today*, 11(1), 20–26.
10. Larone, D. H. (2011). *Medically important fungi: A guide to identification* (5th ed.). ASM Press.
11. Martinez-Rossi, N. M., Peres, N. T. A., & Rossi, A. (2017). Pathogenesis of dermatophytosis: Sensing the host tissue. *Mycopathologia*, 182(1–2), 215–227.  
<https://doi.org/10.1007/s11046-016-0057-9>
12. Mitra, S. K., Sikdar, A., & Das, P. (1998). Dermatophytes isolated from selected ruminants in India. *Mycopathologia*, 142(1), 13–16.
13. Moretti, A., Agnetti, F., Mancianti, F., Nardoni, S., Righi, C., Moretta, I., Fioretti, D. P., & Papini, M. (2013). Dermatophytosis in animals: Epidemiological, clinical and zoonotic aspects. *Giornale Italiano di Dermatologia e Venereologia*, 148(5), 563–572.
14. Mukhamadiev, R. S., Gataullin, D. H., Akhmetov, A. M., & Khisamov, R. R. (2023). Study of antimycotic activity of substances against dermatophytes of the genus *Microsporum*. *Veterinary Doctor*, 2, 23–27.
15. Sargison, N. D., Scott, P. R., Wilson, D. J., & Penny, C. D. (2002). Ringworm caused by *Trichophyton verrucosum* in sheep flocks. *Veterinary Record*, 150(24), 755–756.  
<https://doi.org/10.1136/vr.150.24.755>
16. Shchelkunova, O. A., & Reshetnikova, T. B. (2012). Clinical and epidemiological features of microsporia and trichophytosis. *Siberian Medical Review*, 1(73), 93–96.
17. Vetlek. (n.d.). *Instructions for the use of the veterinary drug Myxoferron*. Retrieved June 3, 2026, from <https://www.vetlek.ru/directions/?id=398>
18. Vidal. (n.d.). *Instructions for use of the veterinary drug LTF-201 Arm*. Retrieved June 3, 2026, from <https://www.vidal.ru/veterinar/ltf-201-arm-29936>